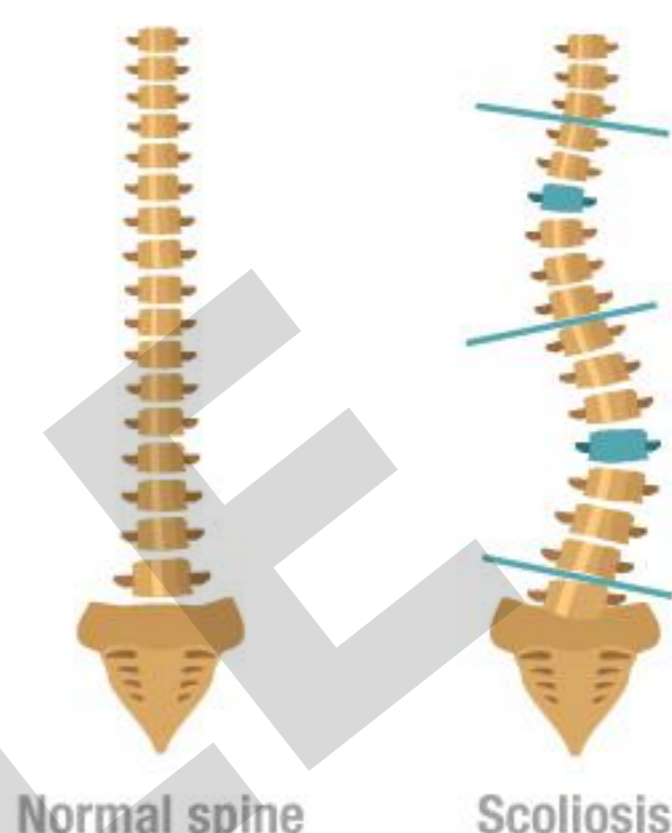


Scoliosis

Clinical examination findings

- Shoulder and waistline asymmetry
- Truncal shift
- Rib prominence on Adam's forward bend test

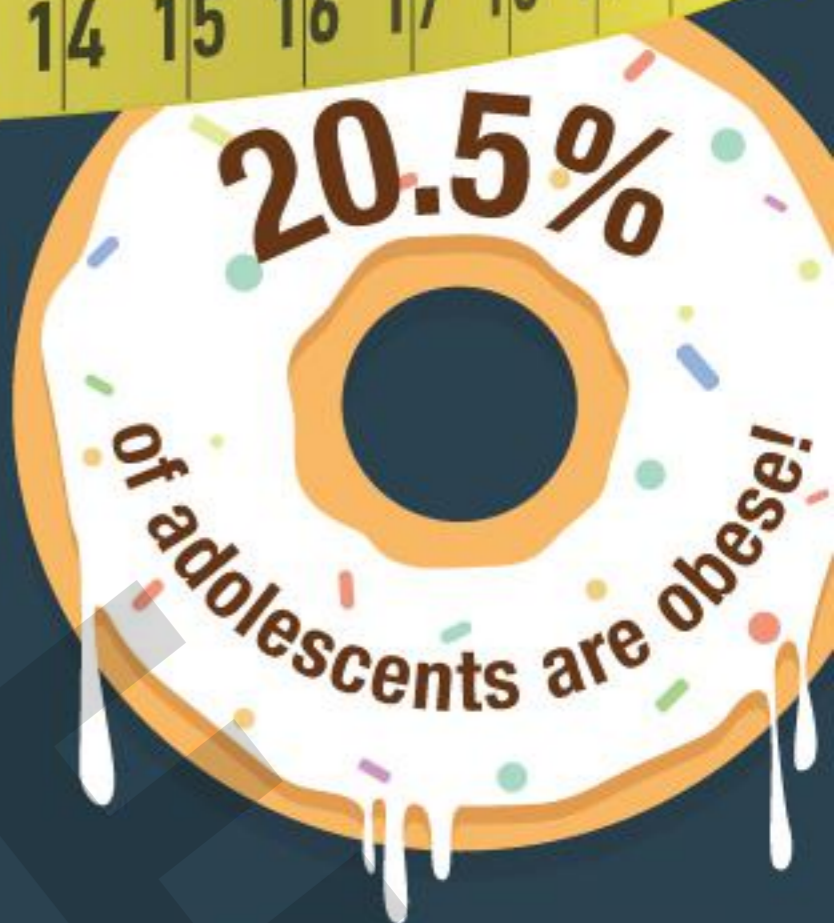

Less apparent in overweight and obese adolescents

Delayed diagnosis

Late referral to an orthopaedic surgeon for treatment

Effects of Obesity in adolescent idiopathic scoliosis (AIS)



2011-2014 National Health and Nutrition Examination Survey

Radiographic measurements

- Preoperative curve magnitude
- Preoperative thoracic kyphosis
- Lumbar lordosis at first follow-up
- Minor curve magnitude at last follow-up

Reported brace compliance was similar between the groups.

588 adolescents (11-17 year olds)
496 girls | 92 boys

454 Healthy weight (HW)
134 Overweight (OW)
71 Obese (OB)

Major curve magnitude

(At first presentation to orthopedic surgeon)

Surgical time

(Posterior spinal fusion)

Postoperative complications

(≥ 2-year follow-up)

BMI%

HW

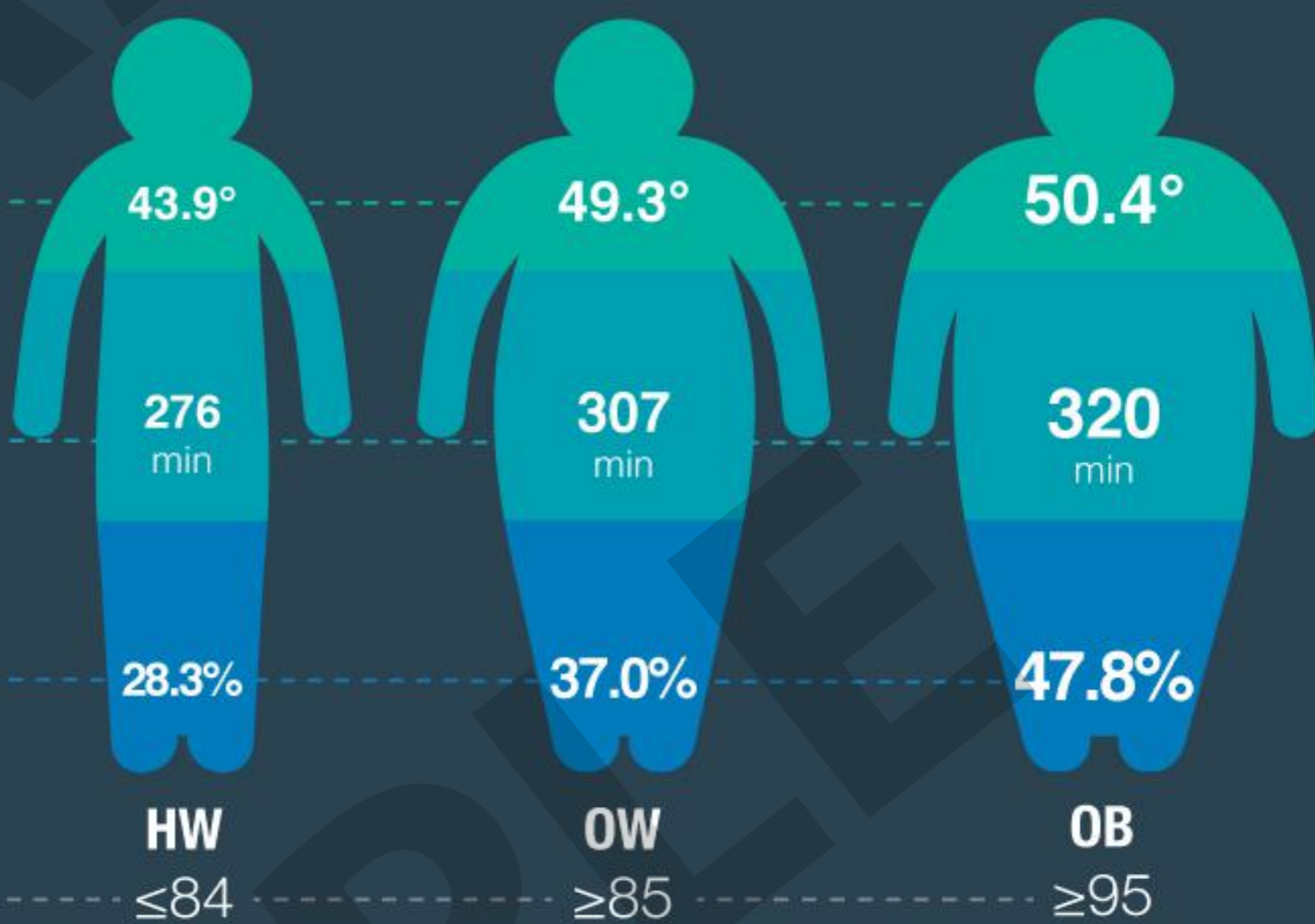
≤84

OW

≥85

OB

≥95



Higher risk of postoperative complications

Larger curve magnitude

Increased surgical times

Outcomes of posterior spinal fusion in **obese** adolescents with AIS

Obese adolescents should be closely monitored for scoliosis to avoid delayed diagnosis and consequent referral for surgical treatment